

# [ CLINICAL COMMENTARY ]

STEPHANIE BOUDREAU, PT, DPT<sup>1</sup> • ED BOUDREAU, PT, OCS<sup>2</sup>  
LAURENCE D. HIGGINS, MD<sup>3</sup> • REG B. WILCOX III, PT, DPT, MS, OCS<sup>4</sup>

## Rehabilitation Following Reverse Total Shoulder Arthroplasty

Conventional total shoulder arthroplasty (TSA) is a widely accepted operative intervention for patients with underlying advanced glenohumeral (GH) joint pathology who have persistent pain and loss of function despite conservative management. These pathologies include osteoarthritis (OA),<sup>5,10,16,17,24,25,28,35,38,39,43,46,50,59,60</sup> rheumatoid arthritis (RA),<sup>5,19,20,23,32,33,35,40,61,62</sup> rotator cuff (RC) tear arthropathy,<sup>4,18,35,54,55,64,65</sup> osteonecrosis,<sup>12,30,31,35,37,41</sup> and fractures of the humeral head.<sup>1,2,5,11,26,34,36,45,51,53</sup> Outcomes of patients with RC deficiency, having undergone a TSA or hemiarthroplasty (HA),

have not been uniform.<sup>4,18,35,54,55,64,65</sup> Given that the joint mechanics are altered in the RC-deficient shoulder, the use of a conventional TSA prosthesis often results in suboptimal outcomes.

Normal GH joint mechanics are not restored following TSA, in the presence of a deficient rotator cuff. The center of rotation of the GH joint typically is still

superiorly shifted because the RC is not able to oppose superior humeral migration. This results in loading of the glenoid component as the RC-deficient humeral head typically migrates superiorly during shoulder elevation. This glenoid loading leads to excessive shearing forces with resultant glenoid component loosening.<sup>22</sup>

For this reason, HA had become the

standard for the replacement of the humeral head in the presence of either severe cuff pathology or an irreparable cuff. Outcomes, however, have been limited in terms of pain relief and range of motion (ROM).<sup>3,18,54,64,65</sup> The expectation for high functional return following HA in the presence of cuff arthropathy is not realistic. ROM and functional outcomes of patients with cuff tear arthropathy following humeral head replacement are typically less than for patients undergoing a TSA for OA. A return of active forward flexion of roughly 90° is a typical outcome for these patients.<sup>35,54,55,65</sup> Generally, this approach provides pain relief, although some patients still have pain from the unresurfaced glenoid. Unfortunately, because there is no RC, functional outcomes are unpredictable, as overhead motion will not likely be achieved.

• **SYNOPSIS:** Reverse or inverse total shoulder arthroplasty (rTSA) is becoming a widely accepted surgical intervention. This procedure is specifically designed for the treatment of glenohumeral (GH) joint arthritis or complex fractures, when associated with irreparable rotator cuff (RC) damage or in the presence of RC arthropathy. Additionally, rTSA is an option for the revision of a previously failed conventional total shoulder arthroplasty (TSA) or hemiarthroplasty (HA) in the RC-deficient shoulder. The physical therapist, surgeon, and patient must take into consideration that the postoperative course for a patient following rTSA should be different than the rehabilitation following a traditional TSA. rTSA has only recently been ap-

proved by the Food and Drug Administration in the United States; however, nearly a 20-year history of its use exists in Europe. To date, we are aware of no peer-reviewed published descriptions of the postoperative rehabilitation for patients having undergone this procedure. The purpose of this paper is to review the indications for rTSA, focusing on underlying pathology, and to outline a rehabilitation protocol founded on basic science principles and our experience working with patients following rTSA. *J Orthop Sports Phys Ther* 2007;37(12):734-743. doi:10.2519/jospt.2007.2562

• **KEY WORDS:** cuff tear arthropathy, inverse total shoulder arthroplasty, physical therapy, shoulder rehabilitation

### Reverse Total Shoulder Arthroplasty

The reverse, or inverse, total shoulder arthroplasty (rTSA), first described by Grammont et al,<sup>27</sup> has recently gained popularity as a treatment option for patients requiring a shoulder replacement for the treatment of GH joint arthritis when it is associated with irreparable RC damage, complex fractures, or for the revision of a previously failed conventional TSA in which the RC tendons are deficient/absent. The rTSA prosthesis has been used in Europe for almost

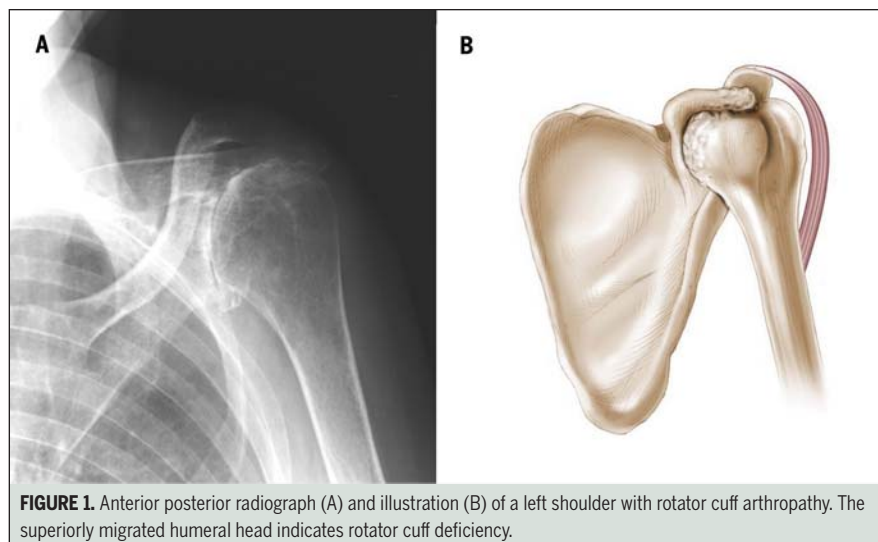
<sup>1</sup>Senior Physical Therapist, Department of Rehabilitation Services, Brigham and Women's Hospital, Boston, MA. <sup>2</sup>Physical Therapist Clinical Specialist, Department of Rehabilitation Services, Brigham and Women's Hospital, Boston, MA. <sup>3</sup>Assistant Professor of Orthopedics, Harvard Medical School, Boston, MA; Chief of Sports Medicine, Brigham and Women's Hospital Chief of the Harvard Shoulder Service, Boston, MA; Orthopedic Surgeon, Department of Orthopedics, Brigham and Women's Hospital, Boston, MA. <sup>4</sup>Clinical Supervisor, Outpatient Services, Department of Rehabilitation Services, Brigham and Women's Hospital, Boston, MA. Address correspondence to Dr Reg B. Wilcox III, Department of Rehabilitation Services, Brigham and Women's Hospital, 75 Francis Street, Boston, MA, 02115. E-mail: [rwilcox@partners.org](mailto:rwilcox@partners.org)

20 years, with good outcomes in regard to pain and function, for the treatment of the RC-deficient or RC-absent shoulder.<sup>9,27,48,52</sup> Despite an almost 2-decade experience with rTSA, we are unaware of any peer-reviewed descriptions of the postoperative rehabilitation for patients having undergone this procedure.

The RC is either absent or minimally functional with the rTSA. Therefore, the rehabilitation for a patient following rTSA is different than the rehabilitation following a traditional TSA. Additionally, as the biomechanics of this prosthesis are markedly different, there is inherent potential for instability due to its design, and precautions for the rTSA are unique and distinctly different than those for TSA and HA. The surgeon, physical therapist, and patient need to take these factors into consideration when establishing the postoperative treatment plan. The purpose of this paper is to review the indications for rTSA and outline a rehabilitation protocol. A better understanding of RC deficiency, the rTSA prosthesis, and postoperative management should enable the physical therapist and surgeon to establish an appropriate postoperative rehabilitation protocol to maximize recovery of function.

### Cuff Tear Arthropathy

Cuff tear arthropathy, first described by Neer,<sup>42,44</sup> is characterized by a severe humeral head collapse following massive tearing of the RC. Neer proposed that inactivity following a massive tear of the RC results in instability of the humeral head and leakage of the GH joint synovial fluid, resulting in destruction of the GH joint articular cartilage, osteoporosis, and ultimately collapse of the humeral head. In addition, as a result of the loss of the RC, the centering forces on the glenoid are lost, altering GH joint biomechanics. This leads to superior migration of the humeral head, and typically the humeral head articulates with the undersurface of the acromion, which, over time, erodes the coracoacromial ligament and the acromioclavicular joint (FIGURE 1).



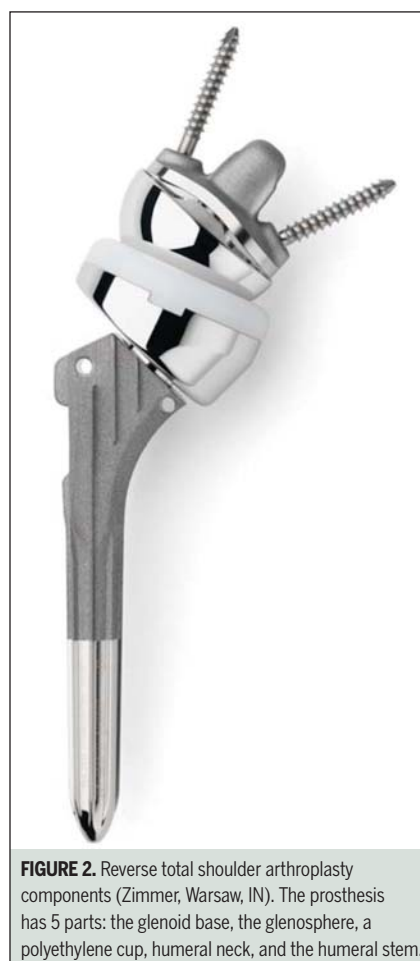**FIGURE 1.** Anterior posterior radiograph (A) and illustration (B) of a left shoulder with rotator cuff arthropathy. The superiorly migrated humeral head indicates rotator cuff deficiency.

### rTSA Biomechanics

The rTSA prosthesis reverses the orientation of the shoulder joint by replacing the glenoid fossa with a glenoid base plate and glenosphere, and the humeral head with a shaft and concave cup (FIGURES 2 and 3). This prosthesis design alters the center of rotation of the shoulder joint by moving it medially and inferiorly. This, subsequently, increases the deltoid moment arm and deltoid tension, which enhances both the torque produced by the deltoid, as well as the line of pull/action of the deltoid. This enhanced mechanical advantage of the deltoid compensates for the deficient RC, as the deltoid becomes the primary elevator of the shoulder joint. This results in an improvement of shoulder elevation and often individuals are able to raise their upper extremity overhead.

### Surgical Outcomes

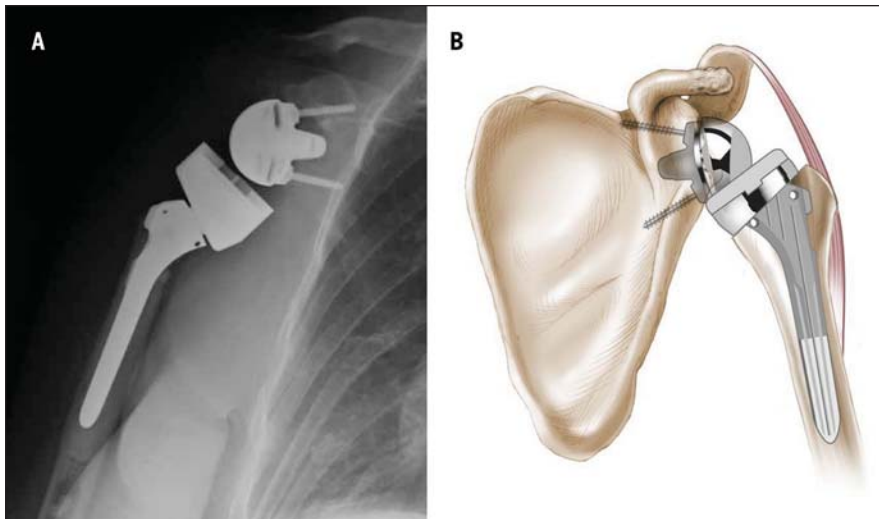
Patients having had a primary rTSA have shown significant increases in active shoulder elevation postsurgery (TABLE). Typically patients regain in excess of 105° of active shoulder elevation.<sup>7-9,13,21,57</sup> These results are superior to those of HA for RC arthropathy.<sup>3,18,54,64,65</sup> Active shoulder rotation in those with cuff deficiency has not been reported to improve following rTSA. Those patients with teres minor deficiency, in particular, have markedly



**FIGURE 2.** Reverse total shoulder arthroplasty components (Zimmer, Warsaw, IN). The prosthesis has 5 parts: the glenoid base, the glenosphere, a polyethylene cup, humeral neck, and the humeral stem.

limited active external rotation (ER) following rTSA. Boileau et al<sup>8</sup> reported that individuals whose teres minor was intact

## [ CLINICAL COMMENTARY ]



**FIGURE 3.** Anterior posterior radiograph of a right shoulder (A) and an illustration of a left shoulder (B) after reverse total shoulder arthroplasty.

### TABLE

#### PUBLISHED OUTCOMES FOR PATIENTS WHO HAVE UNDERGONE REVERSE TOTAL SHOULDER ARTHROPLASTY SECONDARY TO ROTATOR CUFF ARTHROPATHY/DEFICIENCY

Studies	Shoulders (n)	Mean Duration of Follow-up (mo)	Active Forward Elevation (Preoperative/Postoperative)	Constant Score* (Preoperative/Postoperative)
Frankle et al (2005) <sup>21</sup>	66	33	55°/105°	NR
Werner et al (2005) <sup>63</sup>	58	38	42°/100°	29/64
Boileau et al (2006) <sup>7</sup>	45	40	55°/121°	17/58
Sirveaux et al (2004) <sup>57</sup>	80	44	73°/138°	22.6/65.5
Jacobs et al (2001) <sup>29</sup>	7	16	NR	179/56.7
De Buttet et al (1997) <sup>13</sup>	71	24	NR/120°	19.4/59.9
Grammont et al (1987) <sup>27</sup>	16	27	NR	14/69

Abbreviation: NR, not reported.

\* Constant score: range, 0-100, with the higher value indicating better functional status.

had a mean of 15° of active ER. Those who had a deficient teres minor demonstrated no active ER.

### Surgical Considerations

Operative technique is crucial for a good outcome following rTSA. It is critical to realize that the complication rate of this procedure varies depending upon the indication for prosthesis insertion. Primary placement for uncomplicated RC deficiency in the presence of good bone stock is the optimal environment and situation to implant the prosthesis. Complication rates for this application may be

as low as 2% to 3%.<sup>15</sup> The placement of a rTSA prosthesis in a revision setting with poor bone stock, which entails removing a previous humeral component may have a complication rate that exceeds 20%.<sup>7</sup> Common complications include, but are not limited to, component instability or dislocation, nerve damage, intraoperative fracture, infection, hematoma, and hardware failure. Additionally, patient improvement is variable and may be affected by the status of the posterior RC, component placement, previous surgical history, and the integrity of surrounding bone and soft tissues.

The surgical approach needs to be considered when devising the postoperative plan of care. Traditionally a rTSA procedure is performed via a deltopectoral approach,<sup>56</sup> which minimizes surgical trauma to the anterior deltoid; however, some surgeons will use a superior approach, retracting the anterior deltoid from the anterior lateral one third of the clavicle.<sup>6</sup> This technique allows for superior exposure to the GH joint between the retracted anterior deltoid and the clavicle. Upon surgical closure, the anterior deltoid is sutured back to its anatomical location. In these cases early deltoid activity is contraindicated.

### REHABILITATION

**C**OLLABORATION BETWEEN THE surgeon and physical therapist is essential to ensure appropriate rehabilitation for a patient following rTSA. Therapists need to be aware of a number of factors that may affect rehabilitation. Factors may include the patient's preoperative shoulder status, type of implant used, the glenoid and humeral bone quality, the integrity of the remaining RC, concomitant RC repair or tendon transferred, and the overall component stability at the time of surgical reconstruction. There is a wide variance in functional and ROM outcomes following rTSA; therefore, patients must be reminded that their shoulder mechanics and function will have some limitations when compared to their unaffected shoulder. Patients with more active lifestyles typically will require additional education regarding their restrictions to ensure proper longevity of their new prosthesis, as well as to minimize their risk for dislocation. Patients' postoperative activity level expectations need to be considered and managed appropriately when establishing the postoperative rehabilitation plan. There are 3 key postoperative rehabilitation concepts that need to be considered when outlining the care for a patient following rTSA: joint protection, deltoid function, and establishing appropriate functional and ROM expectations.

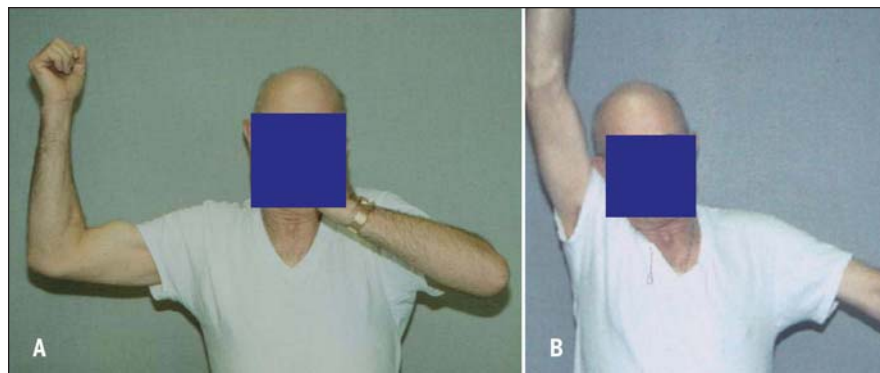


### Joint Protection

In terms of joint protection, postoperative positioning and initial activity need to be appropriately established, as there is a higher risk of shoulder dislocation following rTSA than conventional TSA. Patients with a rTSA typically will not dislocate with the surgical arm in abduction and ER, as generally seen with native shoulders or those who have undergone conventional TSA or HA. If rTSA prostheses dislocate, they do so with the surgical arm in internal rotation (IR) and adduction in conjunction with extension. This position allows the prosthesis to escape anteriorly and inferiorly, which is the position of greatest vulnerability for the rTSA. Functional activities, such as tucking in a shirt and reaching behind one's hip and lower back with the operative upper extremity, are predominantly dangerous activities, particularly in the immediate postoperative phase, and should be the major postoperative precautions for no less than the first 12 weeks.

### Deltoid Function

Enhancement of deltoid function in the absence of the RC following rTSA is the most important rehabilitation concept of the postoperative strengthening phase of recovery. As previously stated, stability and mobility of the shoulder joint are now largely dependent upon the deltoid and periscapular musculature. Therefore, the rehabilitation program and selection of exercise need to progressively emphasize the deltoid and periscapular musculature. A number of patients demonstrate great difficulty in recruiting the deltoid to become the primary mover for shoulder elevation. We recommend the routine use of biofeedback to assist patients in learning recruitment strategies. Numerous biofeedback techniques may be incorporated into the rehabilitation program, including therapists' verbal and tactile cues, surface electromyography, and rehabilitative ultrasound imaging. Upon completion of a successful rehabilitation program, clinicians will likely



**FIGURE 4.** Patient with a deficient left posterior rotator cuff with a positive external rotation lag sign (A) and resultant limited elevation (B). The positive external rotation lag sign of his left shoulder (A) is evident because this patient is unable to maintain an externally rotated position of the shoulder while in abduction, suggesting posterior rotator cuff pathology.

find that the operative upper extremity will demonstrate much higher deltoid recruitment when compared to the contralateral shoulder.

### ROM and Functional Expectations

As previously discussed, any return of active shoulder rotation will be dependent upon the postoperative condition of the teres minor. Hence, the expectation for functional and ROM gains should be set on a case-by-case basis, depending on the underlying pathology, the status of the external rotators, and the extent to which the deltoid and periscapular musculature can be rehabilitated. We have found that those patients who have a negative ER lag sign during the initial strengthening phase of rehabilitation progress quicker in terms of strength gains, functional progression, as well as having a tendency to demonstrate higher active elevation ROM at the time of discharge from physical therapy. The clinician must remember that normal/full active ROM of the shoulder following rTSA is not expected; however, functional active elevation of at least 105° should be anticipated. How critical the status of the posterior cuff is cannot be overstressed. Meticulous preoperative evaluation to assess the capacity to actively externally rotate the humerus has a profound effect on the overall function after rTSA. Significant ER weakness should compel the surgeon to strongly consider a concomitant latissimus dorsi tendon transfer. Active

forward flexion without ER may create a markedly dysfunctional upper extremity and lead to poor patient satisfaction, regardless of the intensity and effort of the patient and physical therapist postoperatively (FIGURE 4).

## POSTOPERATIVE REHABILITATION PROGRAM

**O**UR POSTOPERATIVE rTSA PHYSICAL therapy treatment protocol is outlined in 4 phases: phase I, immediate postsurgical/joint protection; phase II, active ROM/early strengthening; phase III, moderate strengthening; and phase IV, independent/progressive home program. Each phase is structured based on postoperative timelines that respect healing and soft tissue parameters. We advocate the use of an evaluation-based method<sup>47</sup> in conjunction with healing time frames to progress a patient through our protocol, based on intraoperative/postoperative findings, clinical presentation, and achievement of clinical goals/milestones.

### Phase I: Immediate Postsurgical/Joint Protection Phase

Phase I consists of the immediate postsurgical time from postoperative day 1 to the end of the sixth postoperative week. Goals during this phase are to maintain the integrity of the replaced joint, while restoring passive ROM. Family/caregiver

## CLINICAL COMMENTARY

involvement during this time is critical to ensure proper joint protection. Patients that have required rTSA for a revision of a failed conventional TSA need to be managed on a case-by-case basis. Generally, these patients will require a longer immobilization period postoperatively to allow adequate soft tissue healing. We recommend delaying initiating shoulder passive range of motion (PROM) for 3 to 6 weeks postoperatively to ensure adequate bony integrity. In situations where a surgical technique other than a traditional deltopectoral approach was used, such as the superior approach, we recommend that patients start the PROM program 3 to 4 weeks postoperatively to ensure adequate deltoid healing. In addition, these patients should delay the start of deltoid isometrics for at least 4 weeks postoperatively, with active range of motion (AROM) in flexion beginning at approximately 6 weeks and isotonic deltoid strengthening commencing at about 12 weeks postoperatively. This is done to ensure adequate deltoid integrity following surgery. Close collaboration with the referring surgeon regarding the structural integrity of the reconstructed shoulder is essential to determine the ideal time to begin shoulder ROM activity.

During phase I, all shoulder activity should be passive to minimize loads to the newly reconstructed joint. For those patients having a primary rTSA with a traditional deltopectoral approach, PROM may begin after the effects of the interscalene block have resolved, which is to ensure proper deltoid function, as well as to make certain the sensory feedback mechanisms are intact. Active and active assisted elbow, wrist, and hand activity is appropriate, provided that the shoulder joint remains statically positioned. During the first 4 postoperative days, typically while the patient is in inpatient/acute care, PROM is limited in order to minimize strain on the shoulder and to allow for the initial stages of tissue healing. Flexion and elevation in the plane of the scapula are gradually increased as tolerated to 90°. We advise no pure abduction,

as it may place undue stress on the anterior structures of the shoulder. Passive ER should be progressed to approximately 20° to 30° while in the scapular plane. In cases where the subscapularis was repaired, ER ROM parameters may need to be adjusted, as to avoid placing undue stress on the repair. Discussion with the referring surgeon is recommended to clarify any delay or ROM restrictions. Due to the complication of possible dislocation as the result of impaired shoulder stability from the deficient RC, we recommend no IR ROM for the first 6 postoperative weeks. Submaximal pain-free deltoid isometrics and periscapular isometrics with the humerus protected in the scapular plane should begin around the fourth postoperative day. Given that there is minimal to no intact RC following rTSA, the deltoid and periscapular musculature are the primary dynamic restraints, stabilizers, and movers of the GH joint. Beginning deltoid and periscapular isometrics will assist in restoring initial deltoid function and provide stability to the GH joint. Avoidance of shoulder hyperextension while performing posterior deltoid isometrics is critical to minimize the risk of dislocation.

During the third through the sixth postoperative week, the initial postsurgical phase activities are advanced based on the clinical progression and presentation of the patient. As initial soft tissue healing occurs and the patient's sensory feedback improves, it allows a safer progression of passive forward flexion and elevation in the scapular plane to 120°. After the sixth postoperative week, PROM in flexion and elevation in the scapular plane may be advanced to patient tolerance, typically up to 140°. Based on reported outcomes of patients following rTSA, up to 138° of active elevation should be expected.<sup>8,9,21,63</sup> Passive ER ROM may gradually be progressed to 30° to 45°, while respecting the soft tissue constraints of the subscapularis if repaired. The initiation of passive IR may begin during the sixth postoperative week and should only be completed in a protected position of at least 60° of

abduction in the scapular plane to ensure avoidance of IR with adduction.

**Postoperative Immobilization** We typically recommend shoulder immobilization in an abduction-type sling, which supports the humerus in the position of the scapular plane (30° of elevation and abduction) for the first 3 to 4 weeks, except during therapy, bathing, and home exercises, which is consistent with Grammont's<sup>27</sup> postoperative recommendations. The important concept to adhere to regarding positioning following rTSA is that the patient "should always be able to visualize their elbow regardless of what they are doing."<sup>27</sup> This positioning will assist in avoiding shoulder extension and adduction. In addition, when the patient is out of the immobilizer the patient should be advised not to reach across the abdomen/chest wall with the operative upper extremity, as this involves combined IR with adduction and again increases their risk of dislocation. When the posterior cuff has been surgically repaired, its tendon quality is poor. When the posterior capsule tissue integrity is determined to be compromised, as assessed during intraoperative inspection, an ER immobilizer, like the Donjoy Ultrasling 15° ER sling (Donjoy Orthopedics, Vista, CA) is routinely used. The positioning that an ER sling provides enables the humerus to be in the position of the scapular plane, with the added benefit of neutral to 15° of ER. We feel that this position provides an enhanced opportunity for the posterior RC to heal as it promotes immobilization of the repaired posterior cuff in a relatively shortened position during the crucial early postoperative tissue-healing phase. Empirically, there should be less ER stiffness and better tolerance to ER PROM postoperatively with this postoperative positioning. We have not studied whether this alternative positioning has had an impact on postoperative posterior cuff healing and/or muscular performance.

**Cryotherapy** We recommend frequent and continuous cryotherapy postoperatively to assist in the control of pain, minimize swelling and muscle spasm,

and suppress inflammation. While the depth of cooling is unknown, the analgesic effects occur after tissue is cooled to between 10°C to 16°C (50°F-60°F).<sup>49</sup> Current knowledge on the efficacy of cryotherapy for postoperative use is mostly based on poorly controlled studies and empirical evidence. However, Speer et al<sup>58</sup> published the results of a sound, prospective, randomized, controlled clinical trial performed on 50 subjects following shoulder surgery. Cryotherapy was used every 1 to 2 hours for the first 24 hours postoperatively, then was decreased to 4 to 6 times per day (or as needed), until the reassessment time on the 10th postoperative day. Individuals in the cryotherapy group had less pain over the first 24 postoperative hours, with a better potential for sleep and less need for pain medication. Shoulder movement was less painful during therapy by 10 days postoperatively; therefore, these subjects were, in general, better able to follow through with their rehabilitation.

### Phase II: AROM/Early Strengthening Phase (Weeks 6-12)

Phase II consists of the progression from PROM to active assisted range of motion (AAROM) and AROM, as well as the initiation of gentle strengthening, with the primary focus of restoring dynamic shoulder stability and enhanced mechanics. Previously stated dislocation precautions should continue to be enforced. Adequate soft tissue healing at 6 weeks postoperatively allows for AAROM/AROM to be safely initiated. The therapist must carefully monitor quality of movement patterns, motor control, and overall shoulder stability while progressing from AAROM to AROM, to ensure that the shoulder musculature is not inappropriately challenged, which may lead to the development of poor mechanics, unnecessary pain, and compromised joint integrity. AAROM/AROM forward flexion and elevation should be initiated supine where the scapula is stabilized. These activities are then progressed to more functional and dynamically challenging positions of

sitting and standing.

Close monitoring of the patient's tolerance for activity and AROM progression is crucial. One complication not reported in the literature, but that has been observed in patients progressing from the immobilization phase of rehabilitation to AROM and functional activities, is a stress fracture of the acromion. The deltoid is tensioned as the result of the rTSA procedure and, because it is now the primary shoulder elevator, there is a high amount of force generated at the bone-muscle interface of the acromion and deltoid. This factor coupled with traditional risk factors for fractures, such as osteoporosis, history of steroid use, and lengthy immobilization, has led to 2 of our patients developing an acromial stress fracture. These fractures presented insidiously after the patients had gained initial AROM and functional independence, with a rapid decline in AROM tolerance, pain to palpation of the acromion, no loss in PROM, pain with resisted deltoid activation, and negative radiograph imaging. We recommend a conservative management plan for the treatment of nondisplaced acromial stress fractures following rTSA. AROM elevation and deltoid activity should be discontinued for 4 to 6 weeks or until pain has subsided. The modified therapy program should focus on maintaining PROM and restoring IR and ER strength. It may take up to 3 months for a nondisplaced acromial stress fracture to heal.

Close monitoring of the patient's status is suggested to ensure that acromion displacement does not occur. Should displacement occur, surgical intervention may be indicated.

AAROM/AROM IR and ER are initiated and progressed similarly, yet rotation movements should still be completed in the scapular plane. The initiation of IR and ER submaximal isometrics is typically delayed until the eighth week postoperatively, to respect the soft tissue integrity of the teres minor and subscapularis if repaired. Typically the infraspinatus is irreparable and the teres minor

is intact. Initiating IR or ER isometrics at an earlier time in the rehabilitation process could lead to retearing, were any of the RC surgically repaired. If the cuff was not repaired, consultation with the referring surgeon should occur to establish whether IR and ER isometrics might be initiated earlier than 8 weeks postoperatively, as the risk of RC tearing is not a concern.

Gentle periscapular and deltoid isometric activity should progress to isotonic activity between the sixth and eighth postoperative weeks. When isolating the posterior deltoid, patients need to be educated in avoiding shoulder extension beyond neutral, as this could lead to excessive stress placed on the anterior tissues. Initiation of isotonic strengthening should only commence in the presence of adequate mechanics and acceptable AROM of the GH and scapulothoracic joints. If isotonic strengthening is initiated before proper mechanics are established, such activity may reinforce poor mechanics and potentially lead to undue soft tissue stress. When starting isotonic strengthening, we recommend a low-weight, high-repetition program. The utilization of a lawn chair, starting the patient in supine, and gradually increasing the incline until the patient can perform the exercises in sitting, is a useful progression technique.

### Phase III: Moderate Strengthening (Week 12+)

Phase III is initiated when the patient demonstrates appropriate PROM/AAROM/AROM, and is able to isotonicly activate each portion of the deltoid and periscapular musculature, while demonstrating appropriate shoulder mechanics. The patient should be able to tolerate gentle resistive strengthening of the elbow, wrist, and hand of the operative upper extremity. The primary goals of phase III are to advance strengthening and increase functional independence, while maintaining appropriate pain-free shoulder mechanics. Dislocation precautions should continue to be followed for



all static and dynamic activities. We recommend that all strengthening exercises be based on the principles of low weight and high repetition, to enhance shoulder endurance and minimize the risk of injury/dislocation. We have found that most patients following rTSA have achieved functional strength gains by following progressive resisted exercises up to 1.36 kg (3 lb), based on DeLorme's<sup>14</sup> principles of progressive resistive exercise. Sudden lifting, pushing, and jerking motions should be avoided indefinitely to minimize the risk of injury/dislocation.

#### Phase IV: Continued Home Program (Typically Months 4+)

Phase IV commences when the patient has been discharged from skilled physical therapy and is continuing with a home exercise program. To enter phase 4, the patient should be able to demonstrate functional pain-free shoulder AROM and be independent with an appropriate strengthening program. Ultimate postoperative shoulder ROM is typically 80° to 120° of elevation, with functional ER up to 30°. Functional use of the operative shoulder is demonstrated by a return to light household work and leisure activities, as recommended by the patient's surgeon and physical therapist. Typically a 4.5- to 6.8-kg (10- to 15-lb) bilateral, upper extremity lifting limit should be followed indefinitely, to ensure that the operative shoulder is not strained beyond its structural integrity.

## SUMMARY

THE POPULARITY OF THE rTSA IS growing exponentially. We have proposed a protocol for rehabilitation following rTSA (Appendix). To date, the optimal postoperative rehabilitation plan of care has not been established and minimal research regarding the long-term results of patients following rTSA is available. The role of rTSA in the management of RC arthropathy appears to be clinically sound, as it alters the mechanics of the shoulder to enhance deltoid

function in the absence of a competent RC. Hence, the postoperative course for a patient following rTSA is different than the rehabilitation following a traditional TSA. The physical therapist, surgeon, and patient should work together when establishing the postoperative rehabilitation plan. Further research is needed regarding the long-term results of rTSA and optimal postoperative rehabilitation.

## ACKNOWLEDGMENTS

THE AUTHORS WOULD LIKE TO ACKNOWLEDGE Debbie Canoa, PT, DPT and Kathryn Wilson for their assistance with this manuscript. ☺

## REFERENCES

- Antuna SA, Sperling JW, Sanchez-Sotelo J, Cofield RH. Shoulder arthroplasty for proximal humeral malunions: long-term results. *J Shoulder Elbow Surg.* 2002;11:122-129.
- Antuna SA, Sperling JW, Sanchez-Sotelo J, Cofield RH. Shoulder arthroplasty for proximal humeral nonunions. *J Shoulder Elbow Surg.* 2002;11:114-121.
- Arntz CT, Jackins S, Matsen FA, 3rd. Prosthetic replacement of the shoulder for the treatment of defects in the rotator cuff and the surface of the glenohumeral joint. *J Bone Joint Surg Am.* 1993;75:485-491.
- Arntz CT, Matsen FA, 3rd, Jackins S. Surgical management of complex irreparable rotator cuff deficiency. *J Arthroplasty.* 1991;6:363-370.
- Barrett WP, Franklin JL, Jackins SE, Wyss CR, Matsen FA, 3rd. Total shoulder arthroplasty. *J Bone Joint Surg Am.* 1987;69:865-872.
- Bayley I, Kessel L. *Shoulder Surgery.* New York, NY: Springer-Verlag; 1982.
- Boileau P, Watkinson D, Hatzidakis AM, Hovorka I. Neer Award 2005: The Grammont reverse shoulder prosthesis: results in cuff tear arthritis, fracture sequelae, and revision arthroplasty. *J Shoulder Elbow Surg.* 2006;15:527-540.
- Boileau P, Watkinson DJ, Hatzidakis AM, Balg F. Grammont reverse prosthesis: design, rationale, and biomechanics. *J Shoulder Elbow Surg.* 2005;14:147S-161S.
- Boulahia A, Edwards TB, Walch G, Baratta RV. Early results of a reverse design prosthesis in the treatment of arthritis of the shoulder in elderly patients with a large rotator cuff tear. *Orthopedics.* 2002;25:129-133.
- Boyd AD, Jr., Thornhill TS. Surgical treatment of osteoarthritis of the shoulder. *Rheum Dis Clin North Am.* 1988;14:591-611.
- Cheng SL, Mackay MB, Richards RR. Treatment of locked posterior fracture-dislocations of the shoulder by total shoulder arthroplasty. *J Shoulder Elbow Surg.* 1997;6:11-17.
- Cushner MA, Friedman RJ. Osteonecrosis of the Humeral Head. *J Am Acad Orthop Surg.* 1997;5:339-346.
- De Buttet A, Bouchon Y, Capon D, Delfosse J. Grammont shoulder arthroplasty for osteoarthritis with massive rotator cuff tears: report of 71 cases [abstract]. *J Shoulder Elbow Surg.* 1997;6:197.
- DeLorme T, Wilkins AL. *Progressive Resistance Exercise.* New York, NY: Appleton-Century-Crofts; 1951.
- Deshmukh AV, Koris M, Zurakowski D, Thornhill TS. Total shoulder arthroplasty: long-term survivorship, functional outcome, and quality of life. *J Shoulder Elbow Surg.* 2005;14:471-479.
- Edwards TB, Kadakia NR, Boulahia A, et al. A comparison of hemiarthroplasty and total shoulder arthroplasty in the treatment of primary glenohumeral osteoarthritis: results of a multicenter study. *J Shoulder Elbow Surg.* 2003;12:207-213.
- Fenlin JM, Jr, Ramsey ML, Allardice TJ, Frieman BG. Modular total shoulder replacement. Design rationale, indications, and results. *Clin Orthop Relat Res.* 1994;37-46.
- Field LD, Dines DM, Zabinski SJ, Warren RF. Hemiarthroplasty of the shoulder for rotator cuff arthropathy. *J Shoulder Elbow Surg.* 1997;6:18-23.
- Figgie HE, 3rd, Inglis AE, Goldberg VM, Ranawat CS, Figgie MP, Wile JM. An analysis of factors affecting the long-term results of total shoulder arthroplasty in inflammatory arthritis. *J Arthroplasty.* 1988;3:123-130.
- Figgie MP, Inglis AE, Figgie HE, 3rd, Sobel M, Burstein AH, Kraay MJ. Custom total shoulder arthroplasty in inflammatory arthritis. Preliminary results. *J Arthroplasty.* 1992;7:1-6.
- Frankle M, Siegal S, Pupello D, Saleem A, Mighell M, Vasey M. The Reverse Shoulder Prosthesis for glenohumeral arthritis associated with severe rotator cuff deficiency. A minimum two-year follow-up study of sixty patients. *J Bone Joint Surg Am.* 2005;87:1697-1705.
- Franklin JL, Barrett WP, Jackins SE, Matsen FA, 3rd. Glenoid loosening in total shoulder arthroplasty. Association with rotator cuff deficiency. *J Arthroplasty.* 1988;3:39-46.
- Friedman RJ, Thornhill TS, Thomas WH, Sledge CB. Non-constrained total shoulder replacement in patients who have rheumatoid arthritis and class-IV function. *J Bone Joint Surg Am.* 1989;71:494-498.
- Gartsman GM, Roddey TS, Hammerman SM. Shoulder arthroplasty with or without resurfacing of the glenoid in patients who have osteoarthritis. *J Bone Joint Surg Am.* 2000;82:26-34.
- Goldberg BA, Smith K, Jackins S, Campbell B, Matsen FA, 3rd. The magnitude and durability of functional improvement after total shoulder arthroplasty for degenerative joint disease. *J Shoulder Elbow Surg.* 2001;10:464-469.

26. Goldman RT, Koval KJ, Cuomo F, Gallagher MA, Zuckerman JD. Functional outcome after humeral head replacement for acute three- and four-part proximal humeral fractures. *J Shoulder Elbow Surg.* 1995;4:81-86.
27. Grammont PM, Baulot E. Delta shoulder prosthesis for rotator cuff rupture. *Orthopedics.* 1993;16:65-68.
28. Green A, Norris TR. Shoulder arthroplasty for advanced glenohumeral arthritis after anterior instability repair. *J Shoulder Elbow Surg.* 2001;10:539-545.
29. Jacobs R, Debeer P, De Smet L. Treatment of rotator cuff arthropathy with a reversed Delta shoulder prosthesis. *Acta Orthop Belg.* 2001 Oct;67:344-347.
30. Hasan SS, Romeo AA. Nontraumatic osteonecrosis of the humeral head. *J Shoulder Elbow Surg.* 2002;11:281-298.
31. Hattrup SJ, Cofield RH. Osteonecrosis of the humeral head: results of replacement. *J Shoulder Elbow Surg.* 2000;9:177-182.
32. Hughes M, Neer CS, 2nd. Glenohumeral joint replacement and postoperative rehabilitation. *Phys Ther.* 1975;55:850-858.
33. Kelly IG, Foster RS, Fisher WD. Neer total shoulder replacement in rheumatoid arthritis. *J Bone Joint Surg Br.* 1987;69:723-726.
34. Kralinger F, Schwaiger R, Wambacher M, et al. Outcome after primary hemiarthroplasty for fracture of the head of the humerus. A retrospective multicentre study of 167 patients. *J Bone Joint Surg Br.* 2004;86:217-219.
35. Levy O, Copeland SA. Cementless surface replacement arthroplasty of the shoulder. 5- to 10-year results with the Copeland mark-2 prosthesis. *J Bone Joint Surg Br.* 2001;83:213-221.
36. Mansat P, Guity MR, Bellumore Y, Mansat M. Shoulder arthroplasty for late sequelae of proximal humeral fractures. *J Shoulder Elbow Surg.* 2004;13:305-312.
37. Mansat P, Huser L, Mansat M, Bellumore Y, Rongieres M, Bonneville P. Shoulder arthroplasty for atraumatic avascular necrosis of the humeral head: nineteen shoulders followed up for a mean of seven years. *J Shoulder Elbow Surg.* 2005;14:114-120.
38. Mansat P, Mansat M, Bellumore Y, Rongieres M, Bonneville P. [Mid-term results of shoulder arthroplasty for primary osteoarthritis]. *Rev Chir Orthop Reparatrice Appar Mot.* 2002;88:544-552.
39. Matsoukis J, Tabib W, Mandelbaum A, Walch G. [Shoulder arthroplasty for non-operated anterior shoulder instability with secondary osteoarthritis]. *Rev Chir Orthop Reparatrice Appar Mot.* 2003;89:7-18.
40. McCoy SR, Warren RF, Bade HA, 3rd, Ranawat CS, Inglis AE. Total shoulder arthroplasty in rheumatoid arthritis. *J Arthroplasty.* 1989;4:105-113.
41. Mont MA, Payman RK, Laporte DM, Petri M, Jones LC, Hungerford DS. Atraumatic osteonecrosis of the humeral head. *J Rheumatol.* 2000;27:1766-1773.
42. Neer CS. *Shoulder Reconstruction.* Philadelphia, PA: WB Saunders; 1990.
43. Neer CS, 2nd. Replacement arthroplasty for glenohumeral osteoarthritis. *J Bone Joint Surg Am.* 1974;56:1-13.
44. Neer CS, 2nd, Craig EV, Fukuda H. Cuff-tear arthropathy. *J Bone Joint Surg Am.* 1983;65:1232-1244.
45. Norris TR, Green A, McGuigan FX. Late prosthetic shoulder arthroplasty for displaced proximal humerus fractures. *J Shoulder Elbow Surg.* 1995;4:271-280.
46. Norris TR, Iannotti JP. Functional outcome after shoulder arthroplasty for primary osteoarthritis: a multicenter study. *J Shoulder Elbow Surg.* 2002;11:130-135.
47. Noyes FR, DeMaio M, Mangine RE. Evaluation-based protocols: a new approach to rehabilitation. *Orthopedics.* 1991;14:1383-1385.
48. Nwakama AC, Cofield RH, Kavanagh BF, Loehr JF. Semiconstrained total shoulder arthroplasty for glenohumeral arthritis and massive rotator cuff tearing. *J Shoulder Elbow Surg.* 2000;9:302-307.
49. O'Brien SJ, Warren RF, Schwartz E. Anterior shoulder instability. *Orthop Clin North Am.* 1987;18:395-408.
50. Orfaly RM, Rockwood CA, Jr., Esenyel CZ, Wirth MA. A prospective functional outcome study of shoulder arthroplasty for osteoarthritis with an intact rotator cuff. *J Shoulder Elbow Surg.* 2003;12:214-221.
51. Pritchett JW, Clark JM. Prosthetic replacement for chronic unreduced dislocations of the shoulder. *Clin Orthop Relat Res.* 1987;89-93.
52. Rittmeister M, Kerschbaumer F, Grammont reverse total shoulder arthroplasty in patients with rheumatoid arthritis and nonreconstructible rotator cuff lesions. *J Shoulder Elbow Surg.* 2001;10:17-22.
53. Rowe CR, Zarins B. Chronic unreduced dislocations of the shoulder. *J Bone Joint Surg Am.* 1982;64:494-505.
54. Sanchez-Sotelo J, Cofield RH, Rowland CM. Shoulder hemiarthroplasty for glenohumeral arthritis associated with severe rotator cuff deficiency. *J Bone Joint Surg Am.* 2001;83-A:1814-1822.
55. Sarris IK, Papadimitriou NG, Sotereanos DG. Bipolar hemiarthroplasty for chronic rotator cuff tear arthropathy. *J Arthroplasty.* 2003;18:169-173.
56. Seebauer L, Walter W, Keyl W. Reverse total shoulder arthroplasty for the treatment of defect arthropathy. *Oper Orthop Traumatol.* 2005;17:1-24.
57. Sirveaux F, Favard L, Oudet D, Huquet D, Walch G, Mole D. Grammont inverted total shoulder arthroplasty in the treatment of glenohumeral osteoarthritis with massive rupture of the cuff. Results of a multicentre study of 80 shoulders. *J Bone Joint Surg Br.* 2004;86:388-395.
58. Speer KP, Warren RF, Horowitz L. The efficacy of cryotherapy in the postoperative shoulder. *J Shoulder Elbow Surg.* 1996;5:62-68.
59. Sperling JW, Antuna SA, Sanchez-Sotelo J, Schleck C, Cofield RH. Shoulder arthroplasty for arthritis after instability surgery. *J Bone Joint Surg Am.* 2002;84-A:1775-1781.
60. Sperling JW, Cofield RH, Steinmann SP. Shoulder arthroplasty for osteoarthritis secondary to glenoid dysplasia. *J Bone Joint Surg Am.* 2002;84-A:541-546.
61. Stewart MP, Kelly IG. Total shoulder replacement in rheumatoid disease: 7- to 13-year follow-up of 37 joints. *J Bone Joint Surg Br.* 1997;79:68-72.
62. Waldman BJ, Figgie MP. Indications, technique, and results of total shoulder arthroplasty in rheumatoid arthritis. *Orthop Clin North Am.* 1998;29:435-444.
63. Werner CM, Steinmann PA, Gilbert M, Gerber C. Treatment of painful pseudoparesis due to irreparable rotator cuff dysfunction with the Delta III reverse-ball-and-socket total shoulder prosthesis. *J Bone Joint Surg Am.* 2005;87:1476-1486.
64. Williams GR, Jr., Rockwood CA, Jr. Hemiarthroplasty in rotator cuff-deficient shoulders. *J Shoulder Elbow Surg.* 1996;5:362-367.
65. Zuckerman JD, Scott AJ, Gallagher MA. Hemiarthroplasty for cuff tear arthropathy. *J Shoulder Elbow Surg.* 2000;9:169-172.



**MORE INFORMATION**  
[WWW.JOSPT.ORG](http://WWW.JOSPT.ORG)



## APPENDIX

### REVERSE TOTAL SHOULDER ARTHROPLASTY PROTOCOL

#### Shoulder Dislocation Precautions

Precautions should be implemented for the first 12 wk postoperatively unless surgeon specifically advises patient or therapist differently:

- No shoulder motion behind lower back and hip (no combined shoulder adduction, internal rotation [IR], and extension)
- No glenohumeral (GH) joint extension beyond neutral

Progression to the next phase based on clinical criteria and time frames as appropriate.

#### Phase I: Immediate Postsurgical Phase, Joint Protection (Day 1 to Week 6)

##### Goals

- Patient and family independent with
  - Joint protection
  - Passive range of motion (PROM)
  - Assisting with putting on/taking off sling and clothing
  - Assisting with home exercise program (HEP)
  - Cryotherapy
- Promote healing of soft tissue/maintain the integrity of the replaced joint
- Enhance PROM
- Restore active range of motion (AROM) of elbow/wrist/hand
- Independent with activities of daily living (ADLs) with modifications

##### Precautions

- Sling is worn for 3-4 wk postoperatively. The use of a sling may be extended for a total of 6 wk, often, if it is a revision surgery
- While lying supine, the distal humerus/elbow should be supported by a pillow or towel roll to avoid shoulder extension. Patients should be advised to "always be able to visualize their elbow while lying supine"
- No shoulder AROM
- No lifting of objects with operative extremity
- No supporting of body weight with involved extremity
- Keep incision clean and dry (no soaking/wetting for 2 wk); no whirlpool, jacuzzi, ocean/lake wading for 4 wk

#### Days 1 to 4 (acute care therapy)

- Begin PROM in supine after complete resolution of interscalene block
  - Forward flexion and elevation in the scapular plane in supine to 90°
  - External rotation (ER) in scapular plane to available ROM as

indicated by operative findings, typically around 20°-30°

- No IR range of motion (ROM)
- AROM/active assisted ROM of cervical spine, elbow, wrist, and hand
- Begin periscapular submaximal pain-free isometrics in the scapular plane
- Continuous cryotherapy for first 72 h postoperatively, then frequent application (4-5 times a day for about 20 min)

#### Days 5 to 21

- Continue all exercises as above
- Begin submaximal pain-free deltoid isometrics in scapular plane (avoid shoulder extension when isolating posterior deltoid)
- Frequent (4-5 times a day for about 20 min) cryotherapy

#### Weeks 3 to 6

- Progress exercises listed above
- Progress PROM
  - Forward flexion and elevation in the scapular plane in supine to 120°
  - ER in scapular plane to tolerance, respecting soft tissue constraints
- At 6 wk postoperatively start PROM IR to tolerance (not to exceed 50°) in the scapular plane
- Gentle resisted exercise of elbow, wrist, and hand
- Continue frequent cryotherapy

#### Criteria for progression to the next phase (phase II)

- Patient tolerates shoulder PROM and AROM program for elbow, wrist, and hand
- Patient demonstrates the ability to isometrically activate all components of the deltoid and periscapular musculature in the scapular plane

#### Phase II: AROM, Early Strengthening Phase (Weeks 6 to 12)

##### Goals

- Continue progression of PROM (full PROM is not expected)
- Gradually restore AROM
- Control pain and inflammation
- Allow continued healing of soft tissue/do not overstress healing tissue
- Re-establish dynamic shoulder stability

##### Precautions

- Continue to avoid shoulder hyperextension
- In the presence of poor shoulder mechanics avoid repetitive

## APPENDIX (CONTINUED)

- shoulder AROM exercises/activity
- Restrict lifting of objects to no heavier than a coffee cup
- No supporting of body weight by involved upper extremity

### **Weeks 6 to 8**

- Continue with PROM program
- Begin shoulder active assisted ROM/AROM as appropriate
  - Forward flexion and elevation in scapular plane in supine with progression to sitting/standing
  - ER and IR in the scapular plane in supine with progression to sitting/standing
- Begin gentle GH IR and ER submaximal pain-free isometrics
- Initiate gentle scapulothoracic rhythmic stabilization and alternating isometrics in supine as appropriate. Begin gentle periscapular and deltoid submaximal pain-free isotonic strengthening exercises, typically toward the end of the eighth week
- Progress strengthening of elbow, wrist, and hand
- Gentle GH and scapulothoracic joint mobilizations as indicated (grades I and II)
- Continue use of cryotherapy as needed
- Patient may begin to use hand of operative extremity for feeding and light ADLs

### **Weeks 9 to 12**

- Continue with above exercises and functional activity progression
- Begin AROM supine forward flexion and elevation in the plane of the scapula with light weights of 0.5 to 1.4 kg (1 to 3 lb) at varying degrees of trunk elevation as appropriate (ie, supine lawn chair progression with progression to sitting/standing)
- Progress to gentle GH IR and ER isotonic strengthening exercises

Criteria for progression to the next phase (phase III)

- Improving function of shoulder

- Patient demonstrates the ability to isotonicly activate all components of the deltoid and periscapular musculature and is gaining strength

### **Phase III: Moderate Strengthening (Week 12+)**

Goals

- Enhance functional use of operative extremity and advance functional activities
- Enhance shoulder mechanics, muscular strength, power, and endurance

Precautions

- No lifting of objects heavier than 2.7 kg (6 lb) with the operative upper extremity
- No sudden lifting or pushing activities

### **Weeks 12 to 16**

- Continue with the previous program as indicated
- Progress to gentle resisted flexion, elevation in standing as appropriate

### **Phase IV: Continued Home Program (Typically 4+ Months Postoperative)**

Typically the patient is on a HEP at this stage, to be performed 3-4 times per wk, with the focus on

- Continued strength gains
- Continued progression toward a return to functional and recreational activities within limits, as identified by progress made during rehabilitation and outlined by surgeon and physical therapist

Criteria for discharge from skilled therapy

- Patient is able to maintain pain-free shoulder AROM, demonstrating proper shoulder mechanics (typically 80°-120° of elevation, with functional ER of about 30°)